

## Effects of ethanol on the ultrastructure of the hamster thyroid C-cell

H. Chen<sup>1</sup>, D. Hayakawa<sup>1</sup>, S. Emura<sup>2</sup>, A. Tamada<sup>2</sup>, Y. Ozawa<sup>1</sup>, H. Taguchi<sup>1</sup>, R. Yano<sup>1</sup> and S. Shoumura<sup>1</sup>

<sup>1</sup>Department of Anatomy, and <sup>2</sup>College of Medical Sciences, Gifu University School of Medicine, Gifu, Japan

**Summary.** The morphology of the thyroid C-cells in golden hamsters after short- and long-term treatment with ethanol was studied. Immunohistochemistry was applied to examine the distribution of the C-cells in the thyroid gland. In the short-term experimental animals, the Golgi complexes and the granular endoplasmic reticulum were well developed and the number of the secretory granules was decreased as compared with those of the control animals. These findings suggest that the cellular activity of the thyroid C-cell is stimulated after short-term treatment with ethanol. The morphology of the thyroid C-cells of the long-term experimental animals was similar to that of the controls. It is conceivable that long-term treatment with ethanol does not affect the function of the C-cell.

**Key words:** C-cell, Immunohistochemistry, Ultrastructure, Golden hamster, Ethanol

### Introduction

The increasing incidence of osteoporosis has prompted the research for etiological factors. Among these factors, ethanol has recently been implicated in osteoporosis as a risk factor. Constant consumption of ethanol is associated with disturbance of bones and mineral metabolism (Bikle et al., 1985; Laitinen and Valimaki, 1991; Sampson, 1997). The mechanism of the ethanol-induced bone diseases seems to be complex: a direct effect of ethanol on bone cells and an indirect or modulating effect through calcium regulating hormones such as vitamin D metabolites, parathyroid hormone (PTH), and calcitonin (Bikle et al., 1985; Laitinen and Valimaki, 1991; Sampson, 1997). However, the possibility that ethanol affects the calcium regulating hormones directly has received little attention. Previously, we found morphologically that short-term treatment with ethanol suppressed the hamster

parathyroid activity and long-term treatment stimulated the parathyroid function (Chen et al., 1997, 1998, 1999). In the present study, we observed the morphological changes of the hamster thyroid C-cells to determine whether ethanol affects the function of thyroid C-cells.

### Materials and methods

Six-week-old male golden hamsters with an average body weight of 92 g were divided into 4 groups of 7 animals each. Hamsters were housed in stainless steel cages that were equipped with depressions where food pellets (CE-2, Clea Japan Inc.) were placed. In the short-term experimental group, ethanol was administered by gavage via an intragastric tube. A dose of 6 g/kg of 50% (v/v) ethanol or an equal amount of distilled water (12 ml/kg, short-term control group) was administered. The thyroid glands were removed under sodium pentobarbital anesthesia at 3 hours after administration. Long-term experimental animals were given tap water and 7% ethanol solutions provided in calibrated glass bottles fitted with ball bearing tubes to limit spillage. The ethanol solution intake of a hamster averaged 11.2 ml per day. Long-term control hamsters had tap water available as the only drinking fluid. Three months later, the thyroid glands were removed under sodium pentobarbital anesthesia.

For immunohistochemical study, the thyroid glands were fixed in 4% paraformaldehyde in phosphate buffer (PB) at pH 7.4 for 60 min and cut into 10-µm-thick sections using a cryostat. Immunostain was carried out by the unlabelled peroxidase-anti-peroxidase (PAP) method with a PAP kit (Zymed, South San Francisco, CA, USA). Briefly, the cryostat sections were incubated with the rabbit anti-human calcitonin primary antisera (Biomedica Corp, Foster, CA, USA) diluted 1:1000 in PB containing 0.1% Triton X-100 for 60 min at RT. After being washed in PBS, the sections were incubated successively with goat anti-rabbit bridging antibody and rabbit PAP for 60 min each, with washing in PBS after each step. Visualization was achieved by immersing sections in diaminobenzidine solution. Negative control sections were treated with PBS instead of the primary

*Offprint requests to:* Huayue Chen, Department of Anatomy, Gifu University School of Medicine, 40 Tsukasa-machi, Gifu 500-8705, Japan. Fax: +81-58-265-5840. e-mail: [huayue@cc.gifu-u.ac.jp](mailto:huayue@cc.gifu-u.ac.jp)

antisera and were consistently unstained (not shown). The number of calcitonin-positive C-cells per field was calculated from 25 fields of 5 sections per animal at the magnification of x200. Five animals of each group were used in this study.

Electron microscopy and stereological analysis were performed as described previously (Chen et al., 1999). The blood ethanol concentrations were determined by gas chromatography, and the serum calcium concentrations were measured using a Corning calcium analyzer 940.

All data are presented as mean $\pm$ SEM. Statistical analysis was done using StatView J-4.5 (Abacus Concepts). Group mean values were compared by one-

way analysis of variance (ANOVA) and Fisher's PLSD test for multiple comparisons as the post hoc test. A  $p$  value  $< 0.05$  was considered statistically significant.

## Results

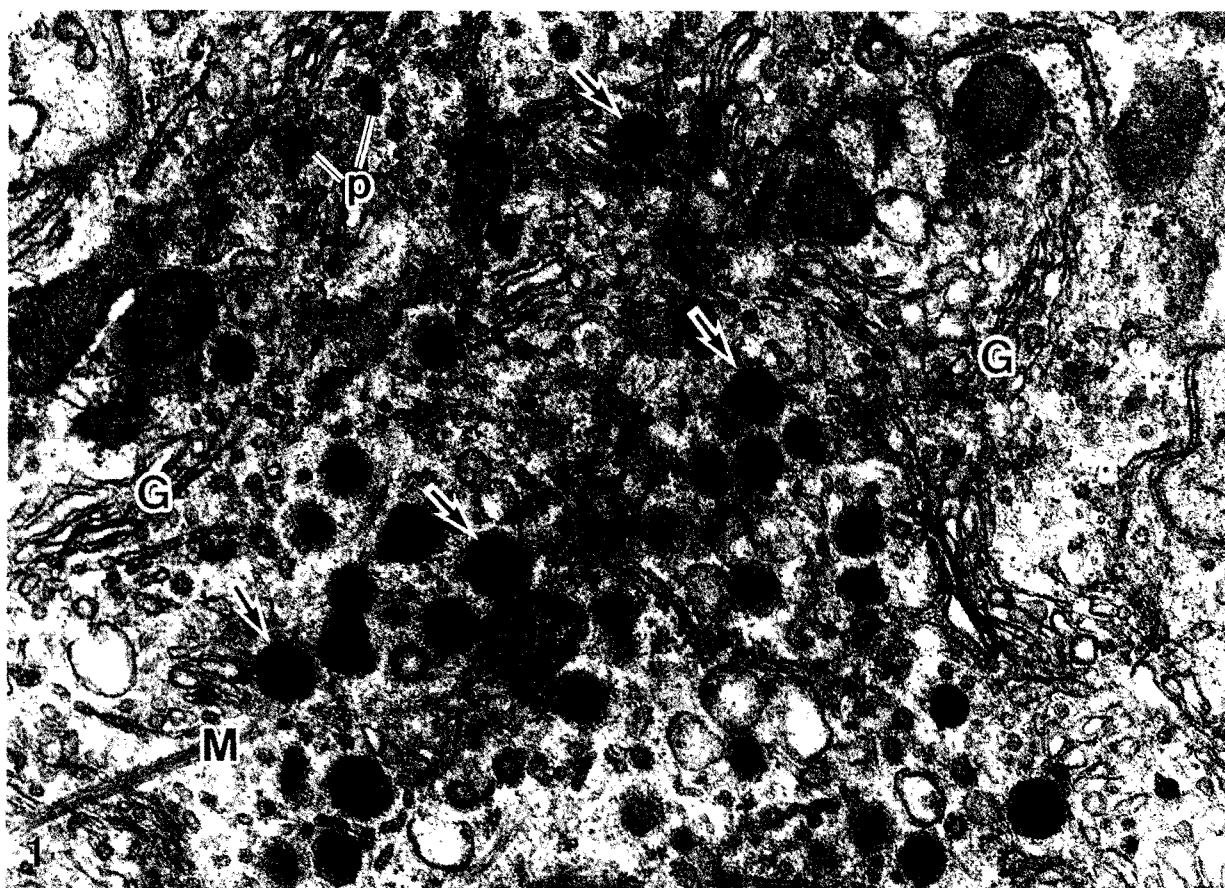
### Blood ethanol and serum calcium concentrations

The mean blood ethanol (mg/ml) and the serum calcium concentrations (mg/100 ml) of the control and ethanol-treated groups are shown in Table 1. The blood ethanol concentration of the short- and long-term experimental animals was significantly high ( $p < 0.05$ ) as compared with that of the control animals. The serum

**Table 1.** Blood ethanol (mg/ml) and serum calcium (mg/100ml) concentrations and the number of immunoreactive C-cells per field.

TIME	PROTOCOL	ETHANOL	CALCIUM	NUMBER OF C-CELLS
Short-term	Control	$<0.1$	$11.05 \pm 0.25$	$18 \pm 7$
	Experiment	$2.28 \pm 0.30^*$	$9.99 \pm 0.20^*$	$21 \pm 8$
Long-term	Control	$<0.1$	$10.88 \pm 0.13$	$23 \pm 9$
	Experiment	$0.33 \pm 0.06^*$	$11.00 \pm 0.19$	$19 \pm 7$

Values are shown in mean $\pm$ SEM; \*:  $p < 0.05$ .



**Fig. 1.** Thyroid C-cells of the short-term control hamster. Golgi complexes (G) are well developed. Numerous secretory granules (arrows) and a few prosecretory granules (p) are seen in the cytoplasm. M: microfilament. x 33,000

calcium concentration of the short-term experimental animals was significantly decreased ( $p < 0.05$ ).

#### *Immunohistochemical findings*

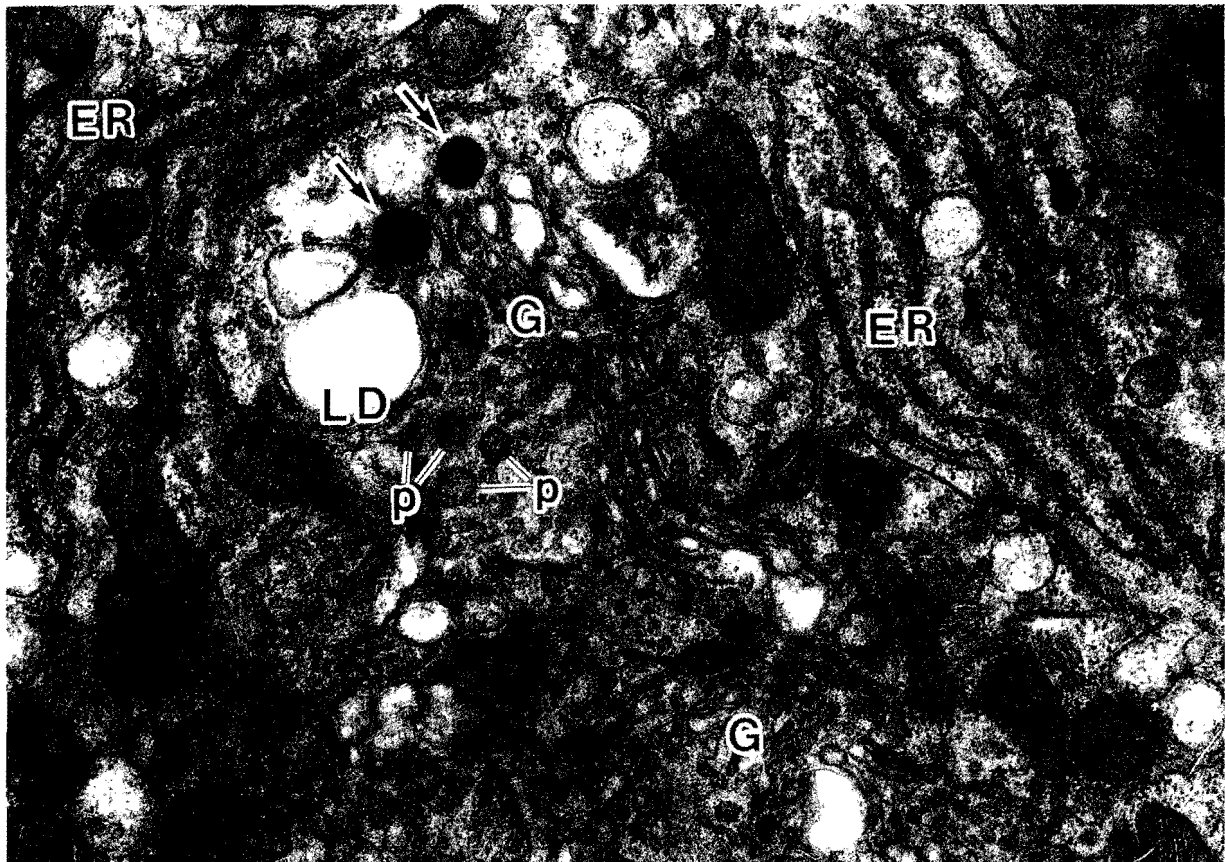
The calcitonin-positive C-cells were brown in color. C-cells were round or oval in shape and were larger than follicular cells. C-cells were present either singly or in small cell clusters. The cells were concentrated in the middle one third of the gland and were not present in the rostral or caudal poles. No C-cells showed direct contact with the thyroid follicular colloid. The number of calcitonin-positive C-cells was similar among 4 groups and there was no significant difference (Table 1). The distribution of calcitonin-positive C-cells was also similar among the 4 groups.

#### *Electron microscopic findings*

In the hamster thyroid glands, C-cells were situated among the follicular epithelial cells and at the peripheral region of thyroid follicles either singularly or as small clusters of two or three cells. They were oval to round and often elongated in shape. C-cells in short-term

control hamsters contained well-developed Golgi complexes, the granular endoplasmic reticulum and numerous mature secretory granules in the cytoplasm (Fig. 1). The mature secretory granules were spherical in shape and 100-300 nm in diameter. These granules had an amorphous electron-dense core and a narrow clear space that was surrounded by a limiting membrane (Fig. 1). A small number of C-cells in control animals contained immature prosecretory granules in the Golgi complex. Microfilaments in bundles were frequently observed in the cytoplasm (Fig. 1). They scattered in the cytoplasm, having no close anatomical relationship with the secretory granules. Some of them crossed the Golgi cisternae (Fig. 1). Lipid droplets and lysosomes were occasionally observed in the cytoplasm.

The most characteristic feature of C-cells in the short-term experimental group was the depletion of mature secretory granules from the cytoplasm (Fig. 2). Most C-cells contained well-developed Golgi complexes and the granular endoplasmic reticulum (Fig. 2). Immature prosecretory granules and vesicles were often aggregated in the well-developed Golgi complex. The mature secretory granules were present predominantly at the periphery of the C-cells.



**Fig. 2.** Thyroid C-cells of the short-term experimental hamster. Golgi complexes (G) and the Cisternae of the granular endoplasmic reticulum (ER) are well developed. A few secretory granules (arrows) are seen in the cytoplasm. p: prosecretory granules; LD: lipid droplet.  $\times 33,000$

The morphology of the C-cells in long-term control and experimental groups resembled that of the short-term control hamsters. Many C-cells had well-developed Golgi complexes, granular endoplasmic reticulum and numerous mature secretory granules (Figs. 3, 4). Bundles of microfilaments were scattered in the cytoplasm (Figs. 3, 4).

#### Stereological analysis of the thyroid C-cell

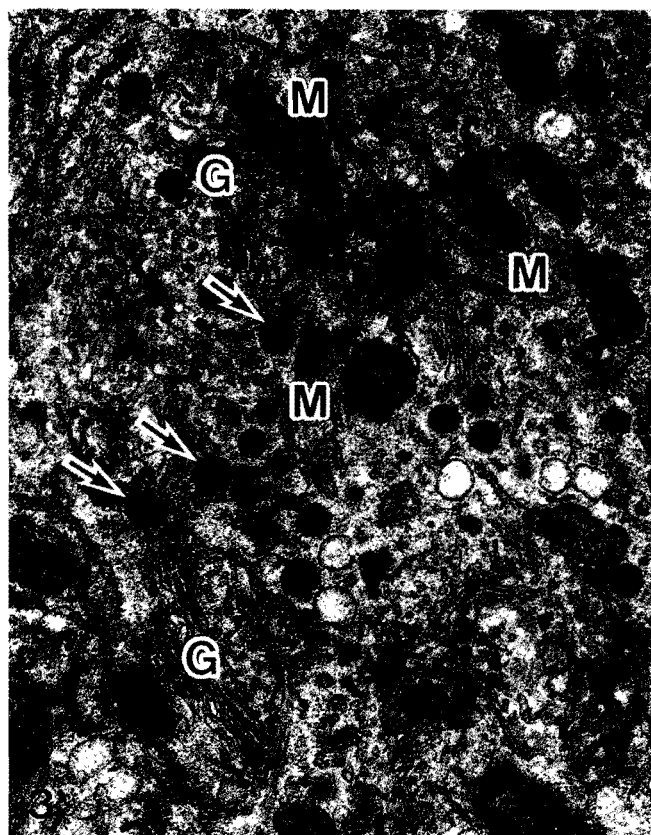
The results obtained from the control and

experimental groups are shown in Table 2. In the thyroid C-cells of the short-term experimental group, the volume density occupied by the cisternae of the granular endoplasmic reticulum and the Golgi complexes was significantly increased ( $p<0.05$ ) as compared with that of the respective control group, while the volume density occupied by the secretory granules was significantly decreased ( $p<0.05$ ) as compared with that of the respective control group. There were no significant differences between the control and experimental groups with regard to mitochondria, lysosomes, lipid droplets

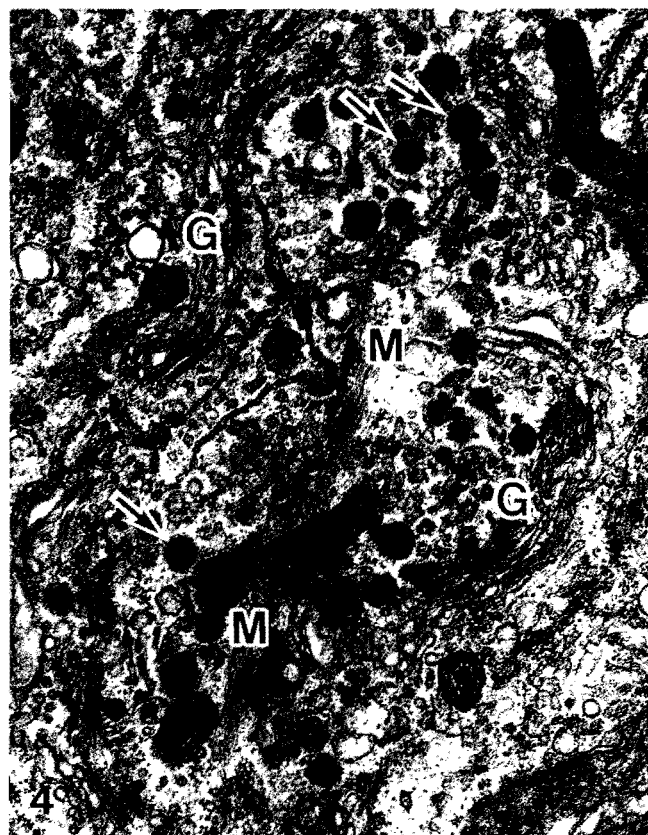
**Table 2.** Volume density (%) of cell components.

TIME	PROTOCOL	MITOCHONDRIA	ROUGH ENDOPLASMIC RETICULUM	GOLGI COMPLEX	LYSOSOMES	LIPID DROPLETS	LARGE VACUOLAR BODY	SECRETORY GRANULES
Short-term	Control	11.15±0.61	11.23±1.36	6.02±0.46	0.16±0.07	0.04±0.01	0.22±0.04	1.26±0.17
	Experiment	10.51±0.94	13.68±1.15*	7.20±0.35*	0.11±0.03	0.03±0.01	0.18±0.04	0.85±0.07*
Long-term	Control	9.70±0.72	11.52±1.37	6.13±0.59	0.19±0.06	0.06±0.02	0.16±0.03	1.48±0.15
	Experiment	10.05±0.75	10.03±0.93	5.86±0.58	0.19±0.05	0.06±0.01	0.19±0.04	1.42±0.14

Values are shown in mean±SEM; \*:  $p<0.05$ .



**Fig. 3.** Thyroid C-cells of the long-term control hamster. Golgi complexes (G) are well developed. Numerous secretory granules (arrows) are seen in the cytoplasm. Bundles of microfilaments (M) are present in the cytoplasm. G: Golgi complexes. x 22,000



**Fig. 4.** Thyroid C-cells of the long-term experimental hamster. Numerous secretory granules (arrows) are seen in the cytoplasm. Bundles of microfilaments (M) are present in the cytoplasm. G: Golgi complexes. x 22,000

and large vacuolar bodies. In the long-term experimental group, the volume density of cell components was similar to that of the respective control group.

## Discussion

Our results showed that the serum calcium concentration of the short-term experimental animals was significantly decreased. This result agrees with previous studies showing that ethanol can produce hypocalcemia in rats and dogs (Peng et al., 1972). Calcitonin is a peptide produced by the thyroid C-cells that functions as an inhibitor of osteoclastic bone resorption. There is currently no convincing evidence that calcitonin deficiency is involved in the pathogenesis of osteoporosis, but it does seem to have potential usefulness as an inhibitor of bone resorption (Sampson, 1997). Williams et al. (1978) gave 0.8 g/kg ethanol to normal nonalcoholic men resulting in a significant increase in serum PTH and plasma calcitonin values. The calcitonin values were 138% of normal at 3 hr. Jorge-Hernandez et al. (1988), on the other hand, found only slightly elevated calcitonin values in a larger study of 52 confirmed alcoholics. Balabanova et al. (1989) administered alcohol to sheep for 20 days and identified increases in both calcitonin and PTH values in plasma and cerebrospinal fluid for only up to 10 days. Later the values remained unchanged. This indicated the development of physical tolerance.

The present study demonstrated that the ultrastructural features of C-cells in golden hamsters were similar to findings in other animals (Nanba and Fujita, 1969; Murakami, 1970; Nunez et al., 1974; Zabel, 1984; Okada et al., 1994). No differences were found among 4 groups as to number and distribution of the C-cells. The cytoplasm of C-cells in the control hamsters was filled with numerous mature secretory granules. Bundles of microfilaments were frequently observed in C-cells of all the groups used. Some of microfilaments crossed the Golgi cisternae. It was reported that microfilaments were present in thyroid C-cells of the dog, rat and mouse. The significance of the microfilaments was not clear, though they appeared to be contractile elements that permit C-cells to change their shape (Welsch et al., 1968; Nunez et al., 1974; Okada et al., 1994). Nunez et al. (1974) reported that large numbers of microfilaments had a close anatomical relationship with the secretory granules in dog thyroid C-cells, indicating considerable sustained secretion of calcitonin. In the present study, such a relationship between the secretory granules and the microfilaments was not found. It was conceivable that the microfilaments played a role in the cell movement (Welsch et al., 1968; Nunez et al., 1974; Okada et al., 1994).

It was shown that the thyroid C-cells of the short-term experimental animals contained well-developed Golgi complexes and the granular endoplasmic reticulum. Immature prosecretory granules were often aggregated near the well-developed Golgi complex. The

mature secretory granules in the cytoplasm decreased markedly. The remaining secretory granules were present predominantly at the periphery of the C-cells. These changes are considered to be induced by stimulation of the synthesis and secretion of the calcitonin in hamster thyroid C-cells. These results are fairly consistent with the findings which indicate an increase in functional activity of the thyroid C-cells (Welsch et al., 1968; Nanba and Fujita, 1969; Murakami, 1970; Nunez et al., 1974; Zabel, 1984; Okada et al., 1994). We consider that these changes are induced by stimulation of the synthesis and release of calcitonin after short-term treatment with ethanol. In this study, the ultrastructure of the thyroid C-cells of the long-term experimental animals was similar to that of the control animals. It is supposed that long-term treatment with ethanol did not affect the cellular activity of the thyroid C-cells. We recently investigated the effects of ethanol on the ultrastructure of the hamster parathyroid glands. The results suggested that the cellular activity of the parathyroid gland was suppressed after short-term treatment with ethanol and stimulated after long-term treatment with ethanol (Chen et al., 1997, 1998, 1999). Accordingly, we consider that the hypocalcemia after short-term treatment with ethanol is probably induced by the suppression of the parathyroid activity and the stimulation of the thyroid C-cell. Long-term treatment with ethanol can stimulate the parathyroid function, but does not affect the thyroid C-cell.

## References

- Balabanova S., Nowak R. and Reinhardt G. (1989). Die rolle der calcium-homöostase-hormone bei der toleranzentwicklung nach drogen- und alkoholkonsum. *Beitr. Gerichtl. Med.* 47, 379-383.
- Bikle D.D., Genant H.K., Cann C., Recker R.R., Halloran B.P. and Strewler G.J. (1985). Bone disease in alcohol abuse. *Ann. Intern. Med.* 103, 42-48.
- Chen H., Hayakawa D., Emura S., Tamada A., Jamali M., Yamahira T., Terasawa K., Isono H. and Shoumura S. (1997). Effects of short-term treatment with ethanol on the ultrastructure of the adult golden hamster parathyroid gland. *Med. Electron Microsc.* 30, 148-153.
- Chen H., Hayakawa D., Emura S., Tamada A., Jamali M., Yamahira T., Yoshida-Terasawa K., Isono H. and Shoumura S. (1998). Ultrastructure of the parathyroid gland of the young golden hamster after short-term treatment with ethanol. *Histol. Histopathol.* 13, 973-979.
- Chen H., Hayakawa D., Emura S., Tamada A., Jamali M., Ozawa Y., Taguchi H., Yano R., Ohtake N. and Shoumura S. (1999). Effects of long-term treatment with ethanol on the the ultrastructure of the golden hamster parathyroid gland. *Histol. Histopathol.* 14, 343-349.
- Jorge-Hernandez J.A., Gonzalez-Reimers C.E., Torres-Ramirez A., Santolaria-Fernandez F., Gonzalez-Garcia C., Batista-Lopez J.N., Pestana-Pestana M. and Hernandez-Nieto L. (1988). Bone changes in alcoholic liver cirrhosis: A histomorphometrical analysis of 52 cases. *Dig. Dis. Sci.* 33, 1089-1095.
- Laitinen K. and Välimäki M. (1991). Alcohol and bone. *Calcif. Tissue Int.* (Suppl) 49, S70-S73.
- Murakami K. (1970). Electron microscopic studies on the effect of long-

- term hypercalcemia on the thyroid parafollicular cell and the parathyroid cell of rats. *Arch. Histol. Jpn.* 32, 155-178.
- Nanba H. and Fujita H. (1969). Fine structure of the thyroid parafollicular cells in normal, vitamin D and  $\text{CaCl}_2$ -treated mice. *Arch. Histol. Jpn.* 30, 283-293.
- Nunez E.A., Hedhammar Å., Wu F-M., Whalen J.P. and Krook L. (1974). Ultrastructure of the parafollicular (C) cells and the parathyroid cell in growing dogs on a high calcium diet. *Lab. Invest.* 31, 96-108.
- Okada H., Merryman J.I., Rosol T.J. and Capen C.C. (1994). Effects of humoral hypercalcemia of malignancy and gallium nitrate on thyroid C-cells in nude mice: Immunohistochemical and ultrastructural investigations. *Vet. Pathol.* 31, 349-357.
- Peng T-C., Cooper C.W. and Munson P.L. (1972). The hypocalcemic effect of ethyl alcohol in rats and dogs. *Endocrinology* 91, 586-593.
- Sampson H.W. (1997). Alcohol, osteoporosis, and bone regulating hormones. *Alcoholism* 21, 400-403.
- Welsch U., Flitney E. and Pearse A.G.E. (1968). Comparative studies on the ultrastructure of the thyroid parafollicular C-cells. *J. Microsc.* 89, 83-94.
- Williams G.A., Bowser E.N., Hargis G.K., Kukreja S.C., Shah J.H., Vora N.M. and Henderson W.J. (1978). Effect of ethanol on parathyroid hormone and calcitonin secretion in man. *Proc. Soc. Exp. Biol. Med.* 159, 187-191.
- Zabel M. (1984). Parafollicular cells of the rat thyroid gland after treatment with vitamin D. *Acta Anat.* 118, 18-22.

Accepted December 12, 1999